

To Study the Changes in OCT Parameters and Visual Outcome in Wet ARMD Patients Pre-and Post-Ranibizumab Injection

Tamboli Kshitij S¹, Shanbhag Nita U², Jain Sanika A³, Zarkar Jay N⁴

Abstract

Purpose: Our study assesses the impact of injection ranibizumab on patients with wet ARMD. We take into account OCT parameters pre- and post- administration of injection ranibizumab. We then correlate the effects of these parameters with visual outcome in these patients. **Methods:** This was a prospective study of 40 eyes of 40 patients in DY Patil Hospital, Nerul, Navi Mumbai over a period of 1 year. All patients were treated with monthly intravitreal ranibizumab injections (0.5 mg/0.05 ml) for 3 months. Changes in foveal photoreceptor layer integrity, choroidal neovascular membrane, diameter, thickness, central macular thickness, subretinal fluid assessment was done by spectral domain OCT at every visit and correlated with final visual outcome. **Results:** It was observed that intravitreal injection ranibizumab has a significant effect on improvement in OCT parameters of these patients. Also, the patients who had significant improvement in OCT had improvement in visual acuity finally. **Conclusion:** Intravitreal ranibizumab is a good choice of treatment in wet ARMD patients. Improvements in OCT could be correlated with visual improvement in these patients.

Keywords: Age related macular degeneration; Choroidal neo-vascularization; Ranibizumab.

How to cite this article:

Tamboli Kshitij S, Shanbhag Nita U, Jain Sanika A, *et al.* To Study the Changes in OCT Parameters and Visual Outcome in Wet ARMD Patients Pre-and Post-Ranibizumab Injection. *Ophthalmol Allied Sci.* 2019;5(3):269-274

Introduction

Choroidal Neo-vascularization (CNV) pathogenesis is said to be due to promotion and inhibition of blood vessel growth by cytokines that cause release of VEGF which bind to endothelial cell receptors. Thus, proliferation and vascular leakage enhances growth of new vessel complex.

Macular photocoagulation study classification classifies CNV as Classic CNV and Occult CNV. Classic CNV can be seen as well demarcated lesions, lacy pattern on fundus fluorescein angiography. Occult CNV is other type which is further classified into type 1 and type 2. Type 1 constitutes lesions with fibro vascular pigment epithelial detachment. Type 2 constitutes lesions late leakage of undetermined source. Lesions were also classified as (predominantly > 50%) classic or minimally classic (CNV < 50%). Ocular angiogenesis is a cause of severe worldwide visual loss and ocular morbidity.¹ However, the development of Anti-vascular Endothelial Growth Factor (anti-VEGF) has revolutionized the treatment of a plethora of ocular angiogenic disease processes.²

OCT provides important information on serous retinal detachments, hemorrhages and sub-retinal neo-vascular membranes that are

Author Affiliation: ¹Third Year Post Graduate Student (MS), ²H.O.D, ³Senior Registrar, ⁴Second Year Resident, Department of Ophthalmology, D.Y. Patil School of Medicine and Hospital, Nerul, Navi Mumbai, Maharashtra 400706, India.

Corresponding Author: Tamboli Kshitij S, Third Year Post Graduate Student (MS), Department of Ophthalmology, D.Y. Patil School of Medicine and Hospital, Nerul, Navi Mumbai, Maharashtra 400706, India.

E-mail: tambolikshitij@gmail.com

Received on 29.09.2019, **Accepted on** 12.11.2019

components of exudative macular degeneration and allows a more precise and detailed analysis of anatomic structures and neo-vascular membrane lesions subtypes. These capabilities facilitate an understanding of the differences between the classic membranes, occult membranes, Retinal Angiomatous Proliferation (RAP) and disciform scars in the natural course of the disease and assess the response to Anti-vascular Endothelial Growth Factor (VEGF) drugs.³

Believing that bevacizumab would not efficiently diffuse through the retina to reach the choroid, Genetech decided to generate a truncated alternative molecule. Ranibizumab (Lucentis) was determined effective by two pivotal trials: The MARINA (minimally classic/occult trial of the anti-VEGF Antibody Ranibizumab in the treatment of neo-vascular ARMD) and ANCHOR (anti-VEGF antibody for the treatment of predominantly classic choroidal neo-vascularization in ARMD) trials. Both of these trials were the first phase 3 trials to show improvement in visual outcomes for all forms of choroidal neo-vascularization and were given FDA approval in 2006.^{4,5}

Our study focused on assessing the OCT parameters and measure the effect of intravitreal injection ranibizumab on these OCT parameters like foveal photoreceptor layer integrity, choroidal neo-vascular membrane, diameter, thickness,

central macular thickness, subretinal fluid after the treatment and vision were been optimally achieved to target. Thus, to correlate the effects of visual parameters with these OCT findings.

Materials and Methods

Our study is a Prospective study with Sample size of 40 eyes of 40 patients. Study site was patients coming to retina clinic in DY Patil Hospital, Nerul, Navi Mumbai. Study duration was a period of 1 year. study began after approval from institutional ethics committee was taken. Well informed written consent was taken from all the participants. All patients were treated with monthly intra-vitreous ranibizumab injections (0.5 mg/0.05 ml) for 3 months by same surgeon. It was noticed that their interval of recurrence also reduced as we decided to treat and extend after 3 months.

Patients initial Best Corrected Visual Acuity (BCVA, by log MAR chart) was noted, dilated fundus examination, Fundus Fluorescein Angiography (FFA) was done, initial OCT (signal strength (> 5/10) by spectral domain) was noted. BCVA at the end of 3 months and OCT at that time was then compared with the initial ones. Assessed the correlation of foveal microstructural changes with visual improvement in neo-vascular ARMD after treatment. Measurement of OCT parameters

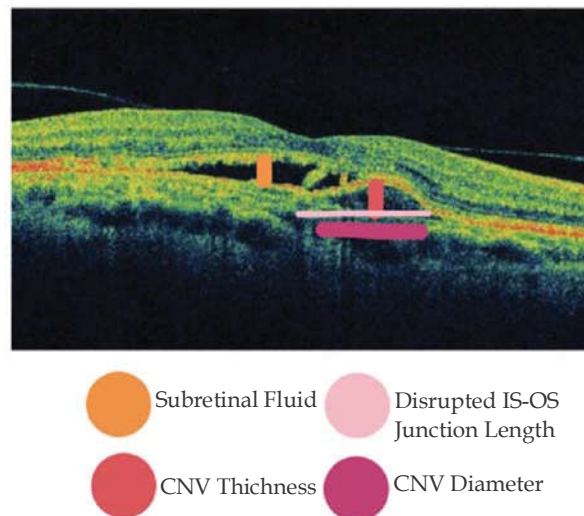


Fig.1: Illustration of measuring OCT parameters in a patient in our study

was done as shown in (**Fig. 1**). CNV diameter, CNV thickness, IS-OS junction, sub-retinal fluid was assessed.

Inclusion criteria's were patients over

50 years of age, diagnosed with wet ARMD. Amongst those willing to participate to follow up. Exclusion criteria's were patients that had other retinal diseases, vitreous hemorrhage, Diabetic retinopathy, epiretinal membrane, myopic

degeneration, venous and arterial occlusion, optic neuropathy, uveitis, history of previous vitreo-retinal surgery, laser photocoagulation or photodynamic therapy.

In performing statistical analysis of data all values were presented as a mean \pm standard deviation. Measurement values of the two Groups on SD-OCT images were compared using the Student's t-test. Bivariate relationships were analyzed using the Pearson correlation co-efficient. Then, multivariate analysis was performed with linear logistic regression over the dependent variable. Chi-square tests were used for comparison of discrete variables among groups. *p* values, < 0.05 were considered statistically significant. For evaluation of intergrader reliability, intraclass correlation co-

efficient of variables (*e.g.*, disrupted IS/OS length, including CNV size) was assessed.

Results

Total 40 eyes were studied, out of which 25 male and 15 females. Age range was from 51 years to 81 years (average, 62.07 ± 8.6 years). Upon doing fundus fluorescein angiography 19 were classic CNVM, 18 were occult CNVM and 3 were unclassified.

The baseline mean BCVA (in log MAR) was 0.61 ± 0.24 while the change in BCVA after intervention was 0.34 ± 0.04 , (Table 1). As other values of baseline and change in CNV central macular thickness, CNV thickness and diameter were analyzed along with sub-retinal fluid and its resolution and initial

Table 1: Showing Oct findings and BCVA values before and after intervention. (adequate doses of injection Ranibizumab)

Pre injection parameters:					
Mean BCVA logMAR	Central macular thickness	CNV thickness	CNV diameter	Subretinal fluid	Disrupted IS-OS length
0.61 ± 0.24	390.12 ± 139.10	229.45 ± 142.14	$2,256.41 \pm 884.46$	Present in 70% eyes	2327.40 ± 1070.85
Post injection parameters:					
Mean BCVA logMAR	Central macular thickness	CNV thickness	CNV diameter	Subretinal fluid	Disrupted IS - OS length
0.95 ± 0.20	514 ± 138.39	304 ± 138.78	2608 ± 842.62	Resolved in 6.8% of eyes	3345 ± 1001.90
Changes in parameters:					
Change in BCVA (logMAR)	Change in Central macular thickness	Change in CNV thickness	Change in CNV diameter	Resolution of Subretinal fluid	Change in disrupted IS/OS length
0.34 ± 0.04	124.12 ± 137.26	75.78 ± 46.62	352 ± 764.68	Present in 63% of eyes	1018.74 ± 976.40
<i>p</i> < 0.05 significant	Not significant	<i>p</i> < 0.05 significant	Not significant	significant	<i>p</i> < 0.05 significant

disrupted IS-OS junction and change in its length disruption (Table 1). Out of these findings, Change in BCVA, CNV thickness, change in sub-retinal fluid and change in disrupted IS/OS junction length were

the parameters that found significant change after intervention in our study (Table 1).

Thus, Changes in oct parameters were measured

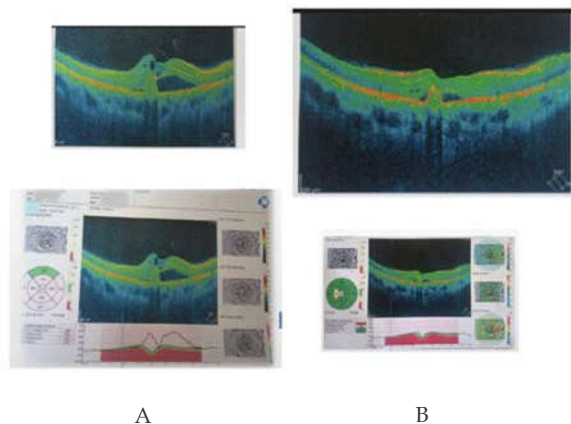


Fig. 2A,B: Illustration showing oct changes in a patient in our study before and after the intervention

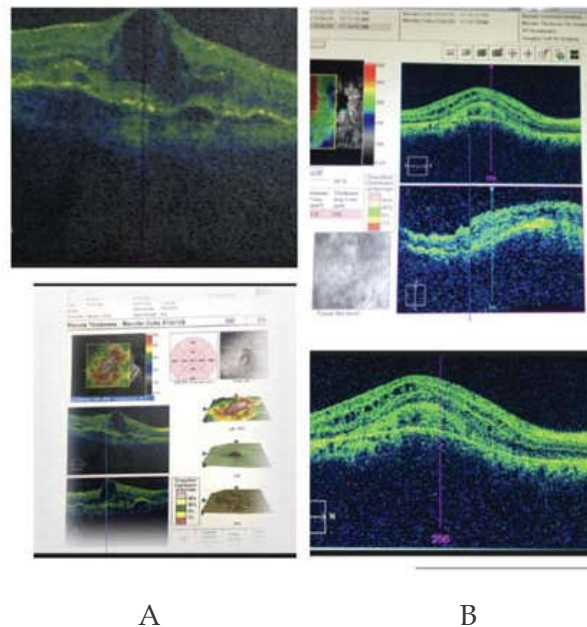


Fig. 3A,B: Illustration showing oct changes in a patient in our study before and after the intervention

as shown in (Fig. 1), illustrates the actual cases in study that improved in oct parameters. (Figs. 2-3) are the Oct pictures of 2 cases in our study: Both of which, the part A of the Fig. shows the initial Oct, while part B shows the Oct after the intervention course of ranibizumab injections.

BCVA change was positively correlated with the change in disrupted IS/OS length ($r=0.614, p=0.05$). Consistent with the restoration of the disrupted IS/OS after IVR, the final BCVA improved. BCVA change was also positively correlated with the change in CNV thickness ($r = 0.652, p = 0.05$). Consistent with the decrease in CNV thickness after IVR, the final BCVA improved.

Discussion

In our study, oct parameters like CNV thickness, diameter, sub-retinal fluid and IS-OS junction receptor length were studied pre- and post-intravitreal injection ranibizumab. Visual acuity improvement after Intravitreal Ranibizumab is correlated significantly with the status of the photoreceptor IS/OS and CNV thickness on SD-OCT after intervention. Visual acuity was most improved when the disrupted IS/OS line was better restored, and CNV thickness was more decreased. However, central macular thickness and CNV diameter had no significant impact after

intervention. Many clinical trials have achieved BCVA improvement after Intravitreal Ranibizumab in neo-vascular AMD. However, information on the microstructural changes correlated with visual improvement has so far been limited. Similar findings have been reported by a study done by Shin *et al.*⁶ and Otani T *et al.*⁷

Frammeet *et al.*⁸ reported on CNV structural changes before and after anti-VEGF monotherapy in 78 eyes with neo-vascular AMD. Quantitative measurement of stable CNV after resolved exudative change showed no significant difference in diameter but revealed a significant reduction in thickness. Similarly, Byun *et al.*⁹ reported a positive response after intravitreal bevacizumab injection in 113 eyes with neo-vascular ARMD. Subretinal tissue thickness, which may reflect CNV thickness, was greater in the non-responder Group than in the responder Group. However, there was no significant difference in CNV diameter between Groups.

In 2006, the antibody fragment, ranibizumab, was approved for use in neo-vascular AMD by the FDA. The landmark ANCHOR and MARINA studies aimed to assess the efficacy of ranibizumab in both classic and minimally classic/occult neo-vascular ARMD, respectively.⁵ The EXCITE trial then directly compared monthly versus quarterly ranibizumab injections over 1 year.¹⁰

HARBOR study¹¹ demonstrated that monthly

doses of 0.5 mg ranibizumab produce the optimum visual results for patients with neo-vascular ARMD. The PrONTO (prospective optical coherence tomography imaging of patients with neo-vascular ARMD treated with intra-ocular ranibizumab) trial was a small, non-randomized, uncontrolled, open-label study which used OCT to vary ranibizumab dosing following a 3-month loading phase.¹² The SUSTAIN (safety and efficacy of a flexible dosing regimen of ranibizumab in neo-vascular age-related macular degeneration) study was a larger, 1 year single arm study which again involved ranibizumab dosing following a 3-month loading phase.¹³

Some clinicians support a “treat and extend” regime, which involves treating monthly until the macula is dry and then incrementally increasing time between injections whilst the macula remains dry.^{14,15} This seems to lead to stabilised visual acuity with a reduction in injections but has not been assessed with a prospective, randomised controlled trial.

Limitations of our study, were relatively small number of patients, OCT angiography technique as is not at our place so, wasn't used in this study, only intravitreal ranibizumab injection was used, no other intravitreal were compared.

In the future, therapeutic strategies should restore and maintain photoreceptor integrity and to decrease and stabilize CNV thickness during neo-vascular AMD treatment. Early detection by screening for the patients who come for visual distortion, cataract and glaucoma evaluation with OCT should be done. OCT should be made mandatory after age 50 in routine health check ups along with cataract. Awareness camps for prevention of blindness should include ARMD too.

Conclusion

It was observed that intravitreal injection ranibizumab has a significant effect on improvement in OCT parameters of these patients. Also, the patients who had significant changes in OCT parameters had improvement in visual acuity finally. Resolution of sub-retinal fluid was significantly noted in most of the patients who had the evidence of it before intravitreal injection. The results of the present study, showed that visual acuity improvement after intravitreal ranibizumab is correlated significantly with the status of the IS/OS junction integrity and CNV thickness on SD-OCT after completion of the loading phase. Visual

acuity was most improved when the disrupted IS/OS line was better restored, and CNV thickness was more decreased. Foveal photoreceptor integrity and CNV thickness seen on SD-OCT are closely associated with visual improvement after intravitreal ranibizumab treatment in patients with neo-vascular AMD.

Many clinical trials including MARINA, ANCHOR, and PrONTO have achieved BCVA improvement after intravitreal ranibizumab in neo-vascular ARMD. However, information on the microstructural changes correlated with visual improvement has so far been limited.

References

1. Brad bowling. Acquired macular disorders; Kanski's Clinical ophthalmology, 8th edition. p. 607.
2. Tah Vikas. Anti-VEGF Therapy and the Retina: An Update; Hindawi Publishing Corporation Journal of Ophthalmology. 2015; Article ID 627674. Available from <https://www.hindawi.com/journals/joph/2015/627674/#B13>.
3. Garcia-Layana, Alfredo. Optical Coherence Tomography in Age-related Macular Degeneration, 2017 July. Available from <http://www.amdbook.org/book/export/html/423>.
4. PJ Rosenfeld, Brown DM, JS Heier. Ranibizumab for neo-vascular age-related macular degeneration. The New England Journal of Medicine. 2006;355(14):1419-31.
5. Brown DM, Kaiser PK, Michels M. Ranibizumab versus verteporfin for neo-vascular age-related macular degeneration. The New England Journal of Medicine. 2006;355(14):1432-44.
6. Shin. Microstructural change and vision in AMD retina, correlation of foveal microstructural changes with vision after anti-vascular endothelial growth factor therapy in age related macular degeneration; Retina. 2013;33:964-70.
7. Otani T. Correlation between visual acuity and foveal microstructural changes in diabetic macular edema. Retina. 2010 May;30(5):774-80.
8. Framme C, Panagakis G, Birngruber R. Effects on choroidal neo-vascularization after anti-VEGF upload using intravitreal ranibizumab, as determined by spectral domain-optical coherence tomography. Invest Ophthalmol Vis Sci. 2010;51:1671-76.
9. Byun YJ, Lee SJ, Koh HJ. Predictors of response after intravitreal bevacizumab injection for neo-vascular age-related macular degeneration. Jpn J Ophthalmol. 2010;54:571-577.
10. Schmidt-Erfurth U, Eldem B, Guymer R. Efficacy and safety of monthly *versus* quarterly ranibizumab

- treatment in neo-vascular age-related macular degeneration: The EXCITE Study. *Ophthalmology*. 2011;118(5):831-839.
11. Busbee BG, Ho AC, Brown DM. Twelve-month efficacy and safety of 0.5 mg or 2.0 mg ranibizumab in patients with subfoveal neo-vascular age-related macular degeneration. *Ophthalmology*. 2013;120(5):1046-056.
 12. Lalwani GA, Rosenfeld PJ, Fung AE. A variable-dosing regimen with intravitreal ranibizumab for neo-vascular age-related macular degeneration: Year 2 of the PrONTO Study. *American Journal of Ophthalmology*. 2009;148(1):43-58.
 13. Holz FG, Amoaku W, Donate J. Safety and efficacy of a flexible dosing regimen of ranibizumab in neo-vascular age-related macular degeneration: The SUSTAIN study. *Ophthalmology*. 2011;118(4):663-71.
 14. Engelbert M, Zweifel SA, and Freund KB. Long-term follow-up for type 1 (subretinal pigment epithelium) neo-vascularization using a modified 'treat and extend' dosing regimen of intravitreal anti-vascular endothelial growth factor therapy. *Retina*. 2010;30(9):1368-75.
 15. Engelbert M, Zweifel SA, and Freund KB. Treat and extend' dosing of intravitreal anti-vascular endothelial growth factor therapy for type 3 neo-vascularization/retinal angiomatous proliferation. *Retina*. 2009;29(10):1424-31.
-